

See discussions, stats, and author profiles for this publication at: <https://www.researchgate.net/publication/306373055>

Crohn's disease successfully treated with the paleolithic ketogenic diet

Article · September 2016

DOI: 10.5348/ijcri-2016102-CR-10690

CITATIONS

3

READS

12,312

5 authors, including:



Csaba Tóth

Paleomedicina Hungary

18 PUBLICATIONS 69 CITATIONS

SEE PROFILE



Andrea Dabóczy

Paleomedicina Hungary

2 PUBLICATIONS 3 CITATIONS

SEE PROFILE



Zsafia Clemens

Paleomedicina Hungary

52 PUBLICATIONS 1,105 CITATIONS

SEE PROFILE

Some of the authors of this publication are also working on these related projects:



Hippocampal and parahippocampal activity during sleep in humans [View project](#)



Serum cholesterol and memory [View project](#)

Crohn's disease successfully treated with the paleolithic ketogenic diet

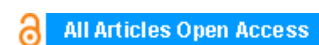
Csaba Tóth, Andrea Dabóczy, Mark Howard, Nicholas J. Miller, Zsófia Clemens

ABSTRACT

Introduction: Crohn's disease is regarded as having no curative treatment. Previous reports on dietary therapy of Crohn's disease indicate no major success.

Case Report: Here we report a severe case of Crohn's disease where we successfully applied the paleolithic ketogenic diet. Dietary therapy resulted in resolution of symptoms, normalized laboratory parameters as well as gradual normalization of bowel inflammation as evidenced by imaging data and normalization of intestinal permeability as shown by the polyethylene glycol (PEG 400) challenge test. The patient was able to discontinue medication within two weeks. Currently, he is on the diet for 15 months and is free of symptoms as well as side effects.

Conclusion: We conclude that the paleolithic ketogenic diet was feasible, effective and safe in the present case.



International Journal of Case Reports and Images (IJCRI)



International Journal of Case Reports and Images (IJCRI) is an international, peer reviewed, monthly, open access, online journal, publishing high-quality, articles in all areas of basic medical sciences and clinical specialties.

Aim of IJCRI is to encourage the publication of new information by providing a platform for reporting of unique, unusual and rare cases which enhance understanding of disease process, its diagnosis, management and clinico-pathologic correlations.

IJCRI publishes Review Articles, Case Series, Case Reports, Case in Images, Clinical Images and Letters to Editor.

Website: www.ijcasereportsandimages.com

Crohn's disease successfully treated with the paleolithic ketogenic diet

Csaba Tóth, Andrea Dabóczy, Mark Howard, Nicholas J. Miller, Zsófia Clemens

ABSTRACT

Introduction: Crohn's disease is regarded as having no curative treatment. Previous reports on dietary therapy of Crohn's disease indicate no major success. **Case Report:** Here we report a severe case of Crohn's disease where we successfully applied the paleolithic ketogenic diet. Dietary therapy resulted in resolution of symptoms, normalized laboratory parameters as well as gradual normalization of bowel inflammation as evidenced by imaging data and normalization of intestinal permeability as shown by the polyethylene glycol (PEG 400) challenge test. The patient was able to discontinue medication within two weeks. Currently, he is on the diet for 15 months and is free of symptoms as well as side effects. **Conclusion:** We conclude that the paleolithic ketogenic diet was feasible, effective and safe in the present case.

Keywords: Crohn's disease, Dietary therapy, Inflammatory bowel disease, Ketogenic diet, Paleolithic diet

How to cite this article

Tóth C, Dabóczy A, Howard M, Miller NJ, Clemens Z. Crohn's disease successfully treated with the paleolithic ketogenic diet. Int J Case Rep Images 2016;7(10):570–578.

Article ID: Z01201609CR10690CT

doi:10.5348/ijcri-2016102-CR-10690

INTRODUCTION

Crohn's disease, an inflammatory disease of the bowel, is regarded as having no cure [1]. Standard treatment which involves steroids, immunosuppressants and biological therapy is aimed at reducing symptoms [1]. Periods of flares and remissions typically alternate, however, the overall course of the disease is progressive. A set of ecological evidence, including a discrepancy between westernized and non-westernized countries in the occurrence of the disease, raises the possibility of lifestyle and/or dietary factors in the etiology of the disease [2]. There have been several attempts to use a dietary intervention in Crohn's disease such as the specific carbohydrate diet [3] and the anti-inflammatory diet [4] as well as elimination-reintroduction diets [5]. Although clinical improvements and reduction of medicines have been reported being associated with these diets we are not aware of any diet inducing complete remission and long-term freedom of medicines at the same time.

The authors of the present report are using a diet referred to as the paleolithic ketogenic diet in the treatment of chronic conditions. So far we have published

Csaba Tóth¹, Andrea Dabóczy¹, Mark Howard², Nicholas J. Miller², Zsófia Clemens^{1,3}

Affiliations: ¹PaleoMedicina Hungary Ltd., Evolutionary Medicine Working Group, Budapest, Hungary; ²Biolab Medical Unit, London, United Kingdom; ³Neurological Department, University of Pécs, Pécs, Hungary.

Corresponding Author: Zsófia Clemens, PhD, PaleoMedicina Hungary Ltd., Evolutionary Medicine Working Group, Hidász u. 3. H-1026, Budapest, Hungary; Department of Neurology, University of Pécs, Rét u. 2, H-7623, Pécs, Hungary; Email: clemenszsofia@gmail.com

Received: 17 April 2016
Accepted: 03 June 2016
Published: 01 September 2016

cases of successful treatment of diabetes type 1 [6, 7] and type 2 [8], epilepsy [9, 10] as well as other conditions [11].

CASE REPORT

Diagnosis

The 14-year-old boy presented with fatigue, low grade fever, iron deficiency anemia, lower abdominal tenderness and perianal dermatitis. He was of short stature for his age. On 30 September 2013 upper and lower endoscopy was performed. The latter showed ulcerative lesion in the terminal ileum. Biopsy was taken from multiple sites and histopathology showed severe inflammation of the terminal ileum and the Bauhin's valve. Signs of mild-to-moderate degree aspecific inflammation were seen in the colon. On laboratory workup inflammatory marker C reactive protein (CRP) was elevated (58 mg/L). He was diagnosed with Crohn's disease.

Standard treatment

At the time of diagnosis onset (on 07 October 2013) the patient was started on mesalazine, metronidazole and pantoprazole. Within ten days, ciprofloxacin and probiotics were added. Given that no improvement was seen immunosuppressant therapy was initiated on 13 November 2013 with azathioprine together with methylprednisolone, potassium citrate, calcium and vitamin D. Given that disease progressed, a year after diagnosis onset (on 25 September 2014), biological therapy was initiated: five cycles of adalimumab were given each two weeks apart. The condition of the patient further deteriorated and therefore on 07 November 2014 exclusive formula feeding was initiated. At this time mesalazine, multivitamin, vitamin D3 and calcium were discontinued. Pantoprazole was discontinued within two weeks. Formula-based nutrition resulted in the resolution of abdominal pain but other symptoms persisted (Table 1, Figures 1 and 2).

Laboratory data

As the disease progressed iron deficiency anemia of the patient worsened. Thrombocyte number showed a decreasing tendency across the course of the standard treatment. Level of inflammatory markers CRP and erythrocyte sedimentation rate (ESR) dropped when initiating the immunosuppressant therapy and steroid but increased thereafter (Table 1, Figure 2).

Imaging

At the time of the diagnosis ultrasound examination performed on 07 October 2013 showed thickening of the terminal ileum and that of the small intestine at multiple sites. No thickening of the colon was seen. Three further follow-up ultrasound examinations were carried out during the next year. This showed progression of

the disease as reflected by increasing diameter of the thickened bowel wall and an increasing intensity of hypervascularization. The last ultrasound out of the four (on 7 November 2014) already indicated the thickening of nearly all bowel segments including the colon ascendens and the colon transversum. Figure 3 shows as the largest diameter of the terminal ileum changed between 7 October 2013 and 7 November 2014.

Magnetic Resonance Enterography

Magnetic resonance enterography performed five weeks after diagnosis onset (on 12 November 2013) indicated thickening of the small intestinal wall at multiple locations. A follow-up magnetic resonance enterography 13 months later, on 16 December 2014, showed an increase in the variability in the diameter of the bowel lumen and narrowing of the lumen (Figure 4). Due to the narrowing the patient was offered surgery in December 2014 which he refused.

Symptoms

Abdominal cramps as well as episodes of low grade fever lessened when initiating the immunosuppressant therapy together with steroid. However, within three months the patient developed bilateral knee pain as a new symptom. Later on his appetite deteriorated. At 12 months after diagnosis onset abdominal cramps increased and episodes of low grade fever returned. The patient reported fatigue along with a deterioration in his school performance. Following the onset of the biological therapy all symptoms persisted. Following the fourth cycle of adalimumab strong abdominal pain emerged abruptly which persisted for several hours. Given this experience and the overall ineffectiveness of the biological therapy the patient decided to stop it. He was put on exclusive enteral nutrition which resulted in a lessening of his abdominal cramps but other symptoms persisted.

Dietary advices while on the standard therapy

The patient was advised to follow a diet free of lactose and low in fat and fibers. Analysis of his diet-symptom diary did not show any consistent association between symptoms and food items.

Intervention with the paleolithic ketogenic diet

Given the ineffectiveness of standard therapies the parents of the child were seeking for alternative options. When we first met the patient he reported bilateral pain and swelling of the knee, frequent episodes of fever and night sweats as well as fatigue. He looked pale. We offered the paleolithic ketogenic diet along with close monitoring of the patient. The patient started the diet on 4 January 2015. The diet is consisting of animal fat, meat, offal and eggs with an approximate 2:1 fat : protein

ratio. Red and fat meats instead of poultry as well as regular intake of organ meats from pork and cattle were encouraged. Grains, milk, dairy, refined sugars, vegetable oils, oilseeds, nightshades and artificial sweeteners were excluded. Small amount of honey was allowed for sweetening. The patient was not taking any supplements. Regular home monitoring of urinary ketones indicated sustained ketosis. Regular laboratory follow-up was used to monitor the course of the disease as well as for giving feedback how to fine tune the diet. The patient was under our close control and gave frequent feedbacks and so we could assess the level of dietary compliance. The patient maintained a high level dietary adherence on the long-term, yet on his birthday, he made a mistake: he has eaten two pieces of commercially available “paleo” cake which contained coconut oil, flour from oilseeds as well as sugar alcohol. Clinical consequences are discussed later. From July 2015 onwards he also consumed small amounts of vegetables and fruits. Given the persistence of certain alterations in laboratory values (mild anemia) on 10 November 2015, despite 10 months on the paleolithic ketogenic diet, we suggested to tighten the diet again. From this time on he did neither consume vegetables and fruits nor vegetable oil containing spices such as cumin and cinnamon.

We obtained written informed consent from the patient for the publication of his case.

RESULTS

Discontinuing medication

Within two weeks after diet onset the patient discontinued azathioprine, the only medicine he was taking at this time. Currently, he is without medicines for 15 months.

Symptoms

The frequent night sweats of the patient disappeared within three weeks after diet onset and thus his sleep improved significantly. The knee pains of the patient began to lessen at 4th week on the diet and completely disappeared by the third month. From this time onwards he regularly went to school by bike (20 km daily). He reported restored energy and increased physical and mental fitness. Although during the eight months before diet onset his weight was declining, following diet onset he began to gain weight. At diet onset his weight was 41 kg and was 152 cm tall (BMI = 17.7). At 12 months after diet onset, his height was 160 cm and weighted 50 kg (BMI: 19.5). The change in his height and weight is depicted in Figure 5. At the time of writing the article he is on the diet for 15 months and is free of symptoms as well as side effects.

Laboratory workup

Laboratory workup including blood and urinary analysis was performed seven times during follow-up.

Urinary ketones were positive on each occasion. Blood glucose was between 5 and 5.4 mmol/l. Renal and liver function as well as ions were normal. His severe iron deficiency anemia was reversed already on the fourth week of the diet: iron level increased from 3.6 $\mu\text{mol/L}$ to 12.1 $\mu\text{mol/L}$. Inflammatory markers including ESR and CRP decreased significantly: at four weeks CRP was 3.75 mg/L while ESR was 3 mm/h (Figure 2). Thereafter inflammatory markers elevated to some extent. Thrombocyte number was already low before diet onset but decreased further following diet onset. The last laboratory follow-up, however, on 14 December 2015, indicated an increase in thrombocyte number (Table 2).

Imaging

Ultrasound examination of the abdomen was carried out five times during follow-up and was performed by the same investigator. The first examination following the onset of the paleolithic ketogenic diet, on 29 January 2015, showed significant improvement. Although wall of the terminal ileum was still thickened hypervascularization was no longer present. Thickening was still seen in the caecum and the ileum but not in the other regions which were described as being affected on the preceding ultrasound examination. A follow-up exam on 09 April 2015 showed further improvement: thickening of the wall of the terminal ileum decreased and no abnormal was seen in any other regions. A next ultrasound which was made following eating the “paleo cakes” showed thickening of the wall of the terminal ileum to as much as 6 mm. On the next examination, on 19 Jun 2015, thickening of the terminal ileum decreased to 4.5 cm. Three months later, on 17 September 2015, the examination showed no abnormality (Figures 2 and 3).

Intestinal permeability test

Intestinal permeability was assessed using a polyethylene glycol (PEG 400) challenge test based on the method of Chadwick et al. [12]. PEG 400 contains a mixture of inert water soluble molecules of 11 different sizes that are absorbed independently of dose, but which display decreasing mucosal transport with increasing molecular size. PEG 400 is also nontoxic, not degraded by intestinal bacteria, not metabolized by tissues, and rapidly excreted in urine. After a 3.0-gram oral dose of PEG, the subject makes a six-hour urine collection. The PEG fractions are acetylated with acetic anhydride, using pyridine as a catalyst, and then quantitated by capillary gas-liquid chromatography. The percentage of each fraction of PEG excreted over 6 hours is calculated.

PEG 400 challenge test performed at four months on the diet (on 18 May 2015) showed increased permeability to PEG between 242 and 418 molecular weight. A follow-up test performed at 10 months on the diet (on 26 November 2015) showed no abnormal intestinal permeability (Figure 6).

Table 1: Laboratory data while on a standard diet and corresponding medications, Dashes indicate that a given parameter was not measured

	04 Oct 2013	17 Oct 2013	25 Nov 2013	17 Dec 2013	27 Mar 2014	04 Sep 2014	10 Nov 2014	normal value	
WBC	9.6	7.5	23.2	13.8	6.3	7.6	7.7	4.5-11.5	G/L
RBC	5.5	5.3	5.6	5.5	4.2	4.4	4.7	4.5-5.9	T/L
Hgb	117	113	130	133	110	119	132	135-170	g/L
Hct	0.38	0.36	0.41	0.41	0.33	0.35	0.39	0.41-0.51	L/L
Thrombocyte	252	285	311	168	128	240	166	150-400	G/L
CRP	23.1	21.1	2.6	2.4	12.3	46.7	19.6	0-5	mg/L
ESR	12	8	1	1	14	25	15	0-15	mm/h
T. protein	59	53.9	57.9	54.4	58.3	61.6	57.3	57-80	g/L
Carbamide	0.8	1.7	4.2	5	3.5	2.7	2.8	2.8-7.2	mmol/L
Creatinine	49	47	44	58	41	45	56	53-100	μmol/L
Sodium	140	142	140	136	-	-	143	135-145	mmol/L
Potassium citrate	4.5	4.1	3.9	4.1	-	-	4.5	3.2-5.1	mmol/L
GOT	11	18	11	10	17	15	15	0-50	U/L
GPT	6	11	12	8	7	7	7	0-50	U/L
GGT	13	23	23	15	11	15	9	0-55	U/L
Iron	-	-	-	-	6.9	3.6	-	12.5-32	μmol/L
formula feeding							x		
adalimumab							x		
multivitamin					x	x			
calcium			x	x	x	x			
vitamin D3			x	x	x	x			
potassium citrate			x	x					
methylprednisolone			x	x					
azathioprine			x	x	x	x	x		
probiotics		x	x						
ciprofloxacin		x							
pantoprazole		x	x	x	x	x	x		
metronidazole		x							
mesalazine		x	x	x	x	x			

Abbreviations: WBC: white blood cell count, RBC: red blood cell count, Hgb: hemoglobin, Hct: hematocrit, CRP: C-reactive protein, ESR: erythrocyte sedimentation rate, T. protein: total protein, GOT: glutamate-oxaloacetate transaminase, GPT: glutamate-pyruvate transaminase, GGT: gamma-glutamyl transferase

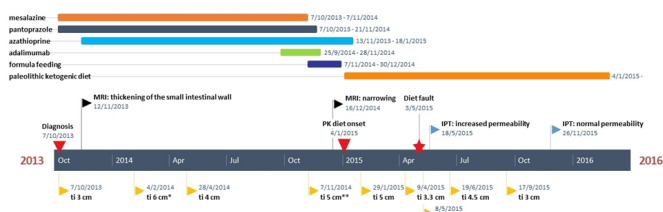


Figure 1: Timeline encompassing the medication of the patient, timing and the result of the MR enterography as well as that of the ultrasound examination. Abbreviations: ti: thickness of the terminal ileum, *: moderate hypervascularization, **: strong hypervascularization, IPT: intestinal permeability test

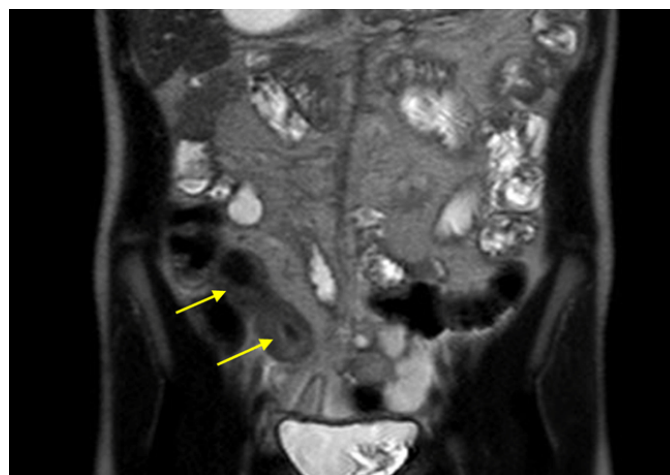


Figure 4: Magnetic resonance enterography on 16 December 2014 showed thickening of the terminal ileum (arrows).

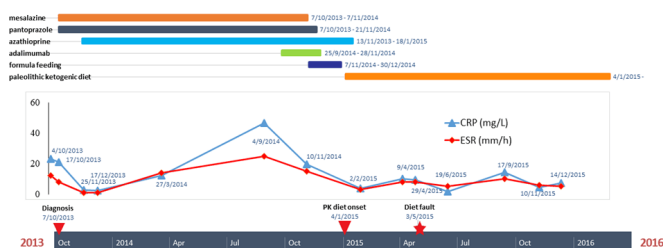


Figure 2: Timeline encompassing medication and the change in the inflammatory markers ESR (erythrocyte sedimentation rate) and CRP (C reactive protein).

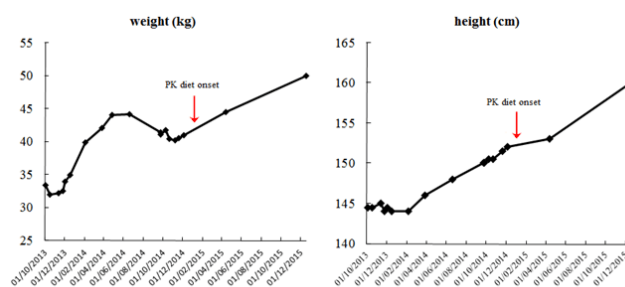


Figure 5: Weight and height of the patient during the 14 months on the standard treatment and following the onset of the dietary therapy.

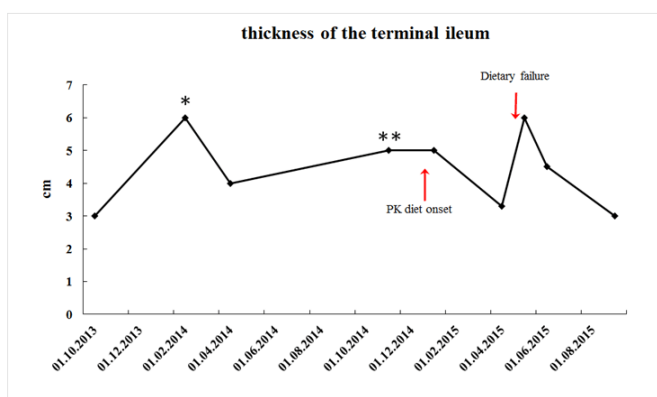


Figure 3: Thickness of the terminal ileum (largest diameter is indicated) seen on ultrasound. Onset of the paleolithic ketogenic diet as well as the occurrence of a dietary failure is indicated with arrows. Note the improvement during the paleolithic ketogenic diet, the relapse following the single episode of dietary failure and the normal results on the last examination. * indicate mild degree hypervascularization while ** high degree hypervascularization.

DISCUSSION

Here we report a case where Crohn’s disease was reversed by the paleolithic ketogenic diet.

Disease symptoms began to improve a few weeks after diet onset. Within 10 months the patient achieved full remission from symptoms as well as normalization of intestinal inflammation as evidenced by imaging data, normalization of laboratory parameters and that of the

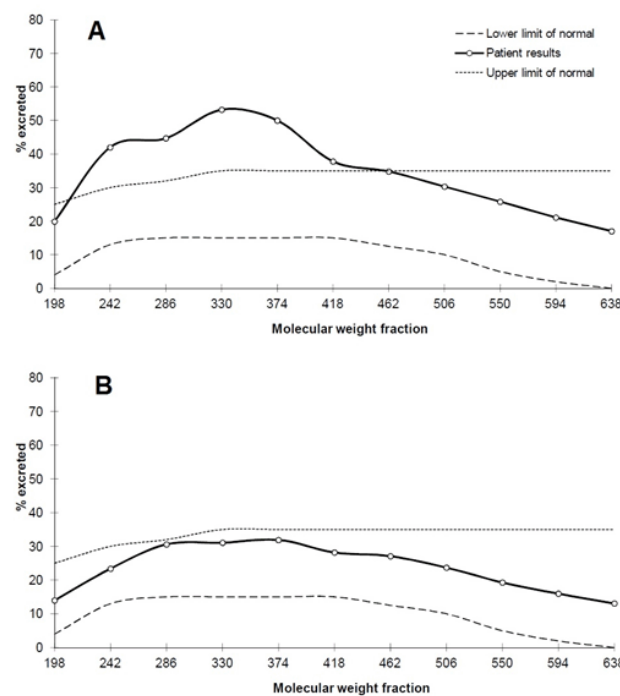


Figure 6: PEG 400 challenge test showing increased intestinal permeability to PEG from molecular weight 242 to molecular weight 418 at four months on the diet (A) while no abnormal at 10 months (B).

Table 2: Laboratory data while on the paleolithic ketogenic diet with no medications. Dashes indicate that a given parameter was not measured

	02 Feb 2015	09 Apr 2015	29 Apr 2015	19 Jun 2015	17 Sep 2015	10 Nov 2015	14 Dec 2015	normal value	
WBC	7.1	8.5	5.7	7.1	7.1	7.8	8	4.5–11.5	G/L
RBC	5	4.8	4.8	5.2	4.8	5.3	5.4	4.5–5.9	T/L
Hgb	145	135	137	147	135	146	151	135–170	g/L
Hct	0.42	0.39	0.4	0.42	0.39	0.43	0.44	0.41–0.51	L/L
Thrombocyte	71	75	68	82	95	65	100	150–400	G/L
CRP	3.75	9.9	9.3	1.8	14.3	4.4	7.1	0–5	mg/L
ESR	3	8	8	5	10	6	5	0–15	mm/h
Total protein	60	62	-	-	63	65	66	57–80	g/L
Carbamid	5.3	6.2	-	-	5.8	6.3	6.9	2.8–7.2	mmol/L
Creatinine	53	63	-	-	48	66	7.3	53–100	µmol/L
Sodium	141	138	-	-	139	140	139	135–145	mmol/L
Potassium	4.3	3.9	-	-	4.1	4.1	4.2	3.2–5.1	mmol/L
GOT	18	20	-	-	21	24	24	0–50	U/L
GPT	12	14	-	-	18	18	18	0–50	U/L
GGT	12	13	-	-	13	13	12	0–55	U/L
Iron	12.1	10.3	-	-	10.6	11	13.7	12.5–32	µmol/L
Uric acid	258	264	-	-	332	329	329	208–428	µmol/L
Glucose	5	5	-	-	5.3	5.2	5.4	3.5–6.1	mmol/L
Magnesium	0.76	0.86	-	-	0.81	0.87	0.89	0.73–1.06	mmol/L
Cholesterol	4.6	4.9	4.7	4.8	4.3	4.1	4.3	<5.2	mmol/L
Triglyceride	0.9	1.46	-	-	0.56	0.93	1.34	<1.7	mmol/L
Fibrinogen	-	-	2.5	2.3	-	-	-	2–4	g/L
Urinary ketones	++	++++	++	+++	+++	++	+		

Abbreviations: WBC: white blood cell count, RBC: red blood cell count, Hgb: hemoglobin, Hct: hematocrit, CRP: C-reactive protein, ESR: erythrocyte sedimentation rate, T. protein: total protein, GOT: glutamate-oxaloacetate transaminase, GPT: glutamate-pyruvate transaminase, GGT: gamma-glutamyl transferase.

intestinal permeability. Aside from a single dietary fault the patient strictly adhered to the diet as assessed by frequent patient feedback, laboratory data and home monitoring of urinary ketones. Given the patient’s severe condition upon the first visit the paleolithic ketogenic diet was started in the strictest form thus containing no vegetables and fruits at all. Such a diet may first sound restrictive but our previous experience indicate that a full fat-meat diet is needed in the most severe cases of Crohn’s disease. In addition, our experience shows that even a single occasion of deviation from diet rules may result in lasting relapse. This was the case in the present patient too where breaking the strict rules (eating the “paleo cakes”) resulted in a thickening of the bowel wall. Based on our experience this is due to the components of the popular paleolithic diet including coconut oil, oil

seeds and sugar alcohols which may trigger inflammation. In contrast, honey, consumed in limited amounts is tolerable and does not cause such symptoms. The significant improvement seen in the last laboratory exam also indicates that the paleolithic ketogenic diet is most effective when containing no plant components at all.

Crohn’s disease is known to be characterized by a progressive worsening of symptoms. Standard therapies may result in a temporary symptom relief but are accompanied by significant side effects [1]. Surgical resection is thought to be inevitable on the long-term [13]. Our patient also failed to respond to immunosuppressive therapies, steroid, biological agents and exclusive formula feeding. Within 14 months after diagnosis onset, he was offered surgery due to the narrowing of the bowel. The paleolithic ketogenic diet reversed the disease from this

very advanced stage. Although Crohn's disease is known to be characterized by an alternation of better and worse periods, a complete remission from a very advanced stage is highly unlikely to be the part of the normal course of the disease.

While on the biological therapy thrombocyte number dropped and continued to decrease while on the diet. Our previous experience does not indicate thrombocytopenia on the paleolithic ketogenic diet. However, low thrombocyte number is a well-known side effect of the use of adalimumab in Crohn's disease [14, 15]. It is also noteworthy that a return to the strictest form of the paleolithic ketogenic diet resulted in an increase in thrombocyte number.

Crohn's disease is regarded as an autoimmune disease. Autoimmune diseases and Crohn's disease specifically have been linked to increased intestinal permeability [16]. Yet currently there is no known means to reverse pathological intestinal permeability [17]. A previous study with the paleolithic diet found no change in intestinal permeability as assessed by the lactulose-mannitol test [18]. As far as we know this is the first documented case where pathological intestinal permeability was reversed as assessed by a diagnostic test.

Experts in the field of evolutionary medicine has long been suggesting that chronic diseases of civilization emerge from a mismatch between our ancient genome and current lifestyles [19, 20]. In recent years an increasing number of studies showed that the metabolic syndrome and associated conditions can be reversed or improved by applying a diet denoted as "paleolithic" (for a review see: [21]). In the paleolithic diet, as described in the implied papers, macronutrient ratios are undefined or variable, as well as that of the ratio of animal/plant foods including the ratio of animal/plant fats. Our clinical experience, however, indicate that the most severe chronic conditions, including the Crohn's disease, can only be reversed by the paleolithic ketogenic diet based on animal fat, meat and offal. A same conclusion was drawn in our previous case study showing that the paleolithic ketogenic diet was more effective than the popular form of the paleolithic diet in the case of Gilbert's syndrome [11]. The paleolithic ketogenic diet we use in the treatment of chronic diseases is close to the evolutionary diet originally proposed by gastroenterologist Voegtlin [22]. With regard to the main principals, background, sustainability and further issues such as vitamin supply while on a meat-fat based diet we refer to the excellent book of Voegtlin [22].

As regards the underlying mechanism, we put forward that normalizing pathological intestinal permeability is crucial in tackling autoimmune diseases, including Crohn's disease. Accordingly, increased intestinal permeability has been shown to predict relapses in Crohn's disease [23]. It is known that under physiological conditions, dietary macromolecules are not transported paracellularly from the intestinal lumen to the blood or the lymph. It has been suggested that certain components of the Western-type diet are able to destroy cell junctions

and thereby compromise the intestinal barrier function [24, 25]. As a result, large molecules including protein fragments and glycoproteins, possessing antigenic properties, may appear in the circulation and promote chronic inflammation [26]. Given their specific structure, these macromolecules may bind to and form complexes with the surface molecules of certain cell types. Such a complex is then destroyed by the immune system through apoptosis [27, 28]. We assume that a continued exposition to these macromolecules may maintain the autoimmune destruction of tissues. We put forward that the animal fat-meat based diet, the only diet humans are evolutionary adapted to, is lacking substances that are destroying the intestinal barrier. A shift toward the paleolithic ketogenic diet may normalize intestinal permeability (as also seen in our patient) and thereby may halt the autoimmune destruction of the affected tissues, in our case the intestine. With the attenuation of the autoimmune process the intestine may regenerate.

CONCLUSION

We conclude that the paleolithic ketogenic diet was effective while producing no side effects in this case of Crohn's disease. In contrast to standard therapeutic approaches which are aimed to control certain components of the disease only, the paleolithic ketogenic diet was able to reverse the cluster of symptoms and abnormalities associated with the disease. Assuming a long term dietary compliance, we believe that the patient would remain disease-free in the future.

Author Contributions

Csaba Tóth – Substantial contributions to conception and design, Acquisition of data, Analysis and interpretation of data, Drafting the article, Revising it critically for important intellectual content, Final approval of the version to be published

Andrea Dabóczy – Acquisition of data, Analysis and interpretation of data, Revising it critically for important intellectual content, Final approval of the version to be published

Mark Howard – Acquisition of data, Analysis and interpretation of data, Revising it critically for important intellectual content, Final approval of the version to be published

Nicholas J. Miller – Acquisition of data, Analysis and interpretation of data, Drafting the article, Revising it critically for important intellectual content, Final approval of the version to be published

Zsófia Clemens – Substantial contributions to conception and design, Acquisition of data, Analysis and interpretation of data, Drafting the article, Revising it critically for important intellectual content, Final approval of the version to be published

Guarantor

The corresponding author is the guarantor of submission.

Conflict of Interest

Authors declare no conflict of interest.

Copyright

© 2016 Csaba Tóth et al. This article is distributed under the terms of Creative Commons Attribution License which permits unrestricted use, distribution and reproduction in any medium provided the original author(s) and original publisher are properly credited. Please see the copyright policy on the journal website for more information.

REFERENCES

1. Akobeng AK. Crohn's disease: current treatment options. *Arch Dis Child* 2008 Sep;93(9):787–92.
2. Barreiro-de Acosta M, Alvarez Castro A, Souto R, Iglesias M, Lorenzo A, Dominguez-Muñoz JE. Emigration to western industrialized countries: A risk factor for developing inflammatory bowel disease. *J Crohns Colitis* 2011 Dec;5(6):566–9.
3. Cohen SA, Gold BD, Oliva S, et al. Clinical and mucosal improvement with specific carbohydrate diet in pediatric Crohn disease. *J Pediatr Gastroenterol Nutr* 2014 Oct;59(4):516–21.
4. Olendzki BC, Silverstein TD, Persuitt GM, Ma Y, Baldwin KR, Cave D. An anti-inflammatory diet as treatment for inflammatory bowel disease: a case series report. *Nutr J* 2014 Jan 16;13:5.
5. Donnellan CF, Yann LH, Lal S. Nutritional management of Crohn's disease. *Therap Adv Gastroenterol* 2013 May;6(3):231–42.
6. Tóth C, Clemens Z. Type 1 diabetes mellitus successfully managed with the paleolithic ketogenic diet. *Int J Case Rep Images* 2014;5:699–703.
7. Tóth C, Clemens Z. A child with type 1 diabetes mellitus (T1DM) successfully treated with the Paleolithic ketogenic diet: A 19-month insulin freedom. *Int J Case Rep Images* 2015;6:752–7.
8. Tóth C, Clemens Z. Successful treatment of a patient with obesity, type 2 diabetes and hypertension with the paleolithic ketogenic diet. *Int J Case Rep Images* 2015;6:161–7.
9. Clemens Z, Kelemen A, Fogarasi A, Tóth C. Childhood absence epilepsy successfully treated with the paleolithic ketogenic diet. *Neurol Ther* 2013 Sep 21;2(1-2):71–6.
10. Clemens Z, Kelemen A, Tóth C. NREM-sleep Associated Epileptiform Discharges Disappeared Following a Shift toward the Paleolithic Ketogenic Diet in a Child with Extensive Cortical Malformation. *Am J Med Case Rep* 2015;3:212–5.
11. Tóth C, Clemens Z. Gilbert's Syndrome Successfully Treated with the Paleolithic Ketogenic Diet. *Am J Med Case Rep* 2015;3:117–20.
12. Chadwick VS, Phillips SF, Hofmann AF. Measurements of intestinal permeability using low molecular weight polyethylene glycols (PEG 400). I. Chemical analysis and biological properties of PEG 400. *Gastroenterology* 1977 Aug;73(2):241–6.
13. Baumgart DC, Sandborn WJ. Crohn's disease. *Lancet* 2012 Nov 3;380(9853):1590–605.
14. Salar A, Bessa X, Muñoz E, Monfort D, Besses C, Andreu M. Infliximab and adalimumab-induced thrombocytopenia in a woman with colonic Crohn's disease. *Gut* 2007 Aug;56(8):1169–70.
15. Casanova MJ, Chaparro M, Martínez S, Vicuña I, Gisbert JP. Severe adalimumab-induced thrombocytopenia in a patient with Crohn's disease. *J Crohns Colitis* 2012 Dec;6(10):1034–7.
16. Hollander D. Crohn's disease--a permeability disorder of the tight junction? *Gut* 1988 Dec;29(12):1621–4.
17. Odenwald MA, Turner JR. Intestinal permeability defects: is it time to treat? *Clin Gastroenterol Hepatol* 2013 Sep;11(9):1075–83.
18. Boers I, Muskiet FA, Berkelaar E, et al. Favourable effects of consuming a Palaeolithic-type diet on characteristics of the metabolic syndrome: a randomized controlled pilot-study. *Lipids Health Dis* 2014 Oct 11;13:160.
19. Cordain L. *The Paleo Diet: Lose Weight and Get Healthy by Eating the Foods You Were Designed to Eat*. New York: John Wiley; 2002.
20. Lindeberg S. *Food and western disease: health and nutrition from an evolutionary perspective*. Chichester: Wiley-Blackwell; 2009.
21. Manheimer EW, van Zuuren EJ, Fedorowicz Z, Pijl H. Paleolithic nutrition for metabolic syndrome: systematic review and meta-analysis. *Am J Clin Nutr* 2015 Oct;102(4):922–32.
22. Voegtlin WL. *The stone age diet: based on in-depth studies of human ecology and the diet of man*. New York: Vantage Press; 1975.
23. Wyatt J, Vogelsang H, Hübl W, Waldhöer T, Lochs H. Intestinal permeability and the prediction of relapse in Crohn's disease. *Lancet* 1993 Jun 5;341(8858):1437–9.
24. de Punder K, Pruijboom L. The dietary intake of wheat and other cereal grains and their role in inflammation. *Nutrients* 2013 Mar 12;5(3):771–87.
25. Lerner A, Matthias T. Changes in intestinal tight junction permeability associated with industrial food additives explain the rising incidence of autoimmune disease. *Autoimmun Rev* 2015 Jun;14(6):479–89.
26. Ménard S, Cerf-Bensussan N, Heyman M. Multiple facets of intestinal permeability and epithelial handling of dietary antigens. *Mucosal Immunol* 2010 May;3(3):247–59.
27. Cordain L, Toohy L, Smith MJ, Hickey MS. Modulation of immune function by dietary lectins in rheumatoid arthritis. *Br J Nutr* 2000 Mar;83(3):207–17.
28. Maverakis E, Kim K, Shimoda M, et al. Glycans in the immune system and The Altered Glycan Theory of Autoimmunity: a critical review. *J Autoimmun* 2015 Feb;57:1–13.

Access full text article on
other devices



Access PDF of article on
other devices



Edorium Journals: An introduction

Edorium Journals Team

About Edorium Journals

Edorium Journals is a publisher of high-quality, open access, international scholarly journals covering subjects in basic sciences and clinical specialties and subspecialties.

Invitation for article submission

We sincerely invite you to submit your valuable research for publication to Edorium Journals.

But why should you publish with Edorium Journals?

In less than 10 words - we give you what no one does.

Vision of being the best

We have the vision of making our journals the best and the most authoritative journals in their respective specialties. We are working towards this goal every day of every week of every month of every year.

Exceptional services

We care for you, your work and your time. Our efficient, personalized and courteous services are a testimony to this.

Editorial Review

All manuscripts submitted to Edorium Journals undergo pre-processing review, first editorial review, peer review, second editorial review and finally third editorial review.

Peer Review

All manuscripts submitted to Edorium Journals undergo anonymous, double-blind, external peer review.

Early View version

Early View version of your manuscript will be published in the journal within 72 hours of final acceptance.

Manuscript status

From submission to publication of your article you will get regular updates (minimum six times) about status of your manuscripts directly in your email.

Our Commitment

Six weeks

You will get first decision on your manuscript within six weeks (42 days) of submission. If we fail to honor this by even one day, we will publish your manuscript free of charge.*

Four weeks

After we receive page proofs, your manuscript will be published in the journal within four weeks (31 days). If we fail to honor this by even one day, we will publish your manuscript free of charge and refund you the full article publication charges you paid for your manuscript.*

Favored Author program

One email is all it takes to become our favored author. You will not only get fee waivers but also get information and insights about scholarly publishing.

Institutional Membership program

Join our Institutional Memberships program and help scholars from your institute make their research accessible to all and save thousands of dollars in fees make their research accessible to all.

Our presence

We have some of the best designed publication formats. Our websites are very user friendly and enable you to do your work very easily with no hassle.

Something more...

We request you to have a look at our website to know more about us and our services.

* Terms and condition apply. Please see Edorium Journals website for more information.

We welcome you to interact with us, share with us, join us and of course publish with us.



Edorium Journals: On Web



Browse Journals

CONNECT WITH US

